

DIAGNOSTICS OF MYOCARDIAL STANNING OF THE LEFT ATRIAL IN LATENT DIASTOLIC DYSFUNCTION OF THE LEFT VENTRICULAR

Baratova M.S., Khamrashaev B.B.

Department of Public Health and Health Care Management Bukhara State Medical Institute named after Abu Ali ibn Sino Bukhara branch of the Republican Scientific Center for Emergency Medical Aid

✓ Resume

Harvard Medical School called the phenomenon of myocardial stunning, which means "stunning". In addition, the question of whether myocardial stunning has clinical significance, since the decrease in myocardial contractility during stunning is reversible, remained controversial. An increase in blood pressure leads to the development of left ventricular (LV) remodeling, which includes the processes of hypertrophy and dilatation, changes in geometry and impaired systolic and diastolic functions. Structural changes in the LV are accompanied by an overload of the left atrium (LA) and its dilatation, which, in turn, leads to stunning of the LA and is a factor predisposing to the development of rhythm disturbances such as ventricular extrasystoles (VE), atrial fibrillation (AF). On the other hand, this rhythm disturbance itself causes LA dilatation. However, recent research data indicate that a more accurate marker of LA structural remodeling is the LA volume index.

Key words: left ventricular remodeling, left atrial stunning, cardiac arrhythmias, VE, AF, arterial hypertension.

ДИАГНОСТИКА СОСТОЯНИЯ МИОКАРДА ЛЕВОГО ПРЕДСЕРДИЯ ПРИ ЛАТЕНТНОЙ ДИАСТОЛИЧЕСКОЙ ДИСФУНКЦИИ ЛЕВОГО ЖЕЛУДОЧКА

Баратова М.С., Хамрашаев Б.Б.

Департамент общественного здравоохранения и управления здравоохранением Бухарский государственный медицинский институт имени Абу Али ибн Сино Бухарский филиал Республиканского научного центра экстренной медицинской помощи

✓ Резюме

Гарвардская медицинская школа назвала феномен «оглушение» миокарда, что означает «оглушение». Кроме того, оставался спорным вопрос о том, имеет ли оглушение миокарда клиническое значение, поскольку снижение сократимости миокарда во время оглушения является обратимым. Повышение артериального давления приводит к развитию ремоделирования левого желудочка (ЛЖ), которое включает процессы гипертрофии и дилатации, изменения геометрии и нарушения систолической и диастолической функций. Структурные изменения ЛЖ сопровождаются перегрузкой левого предсердия (ЛП) и его дилатацией, что, в свою очередь, приводит к оглушению ЛП и является фактором, предрасполагающим к развитию нарушений ритма, таких как желудочковая экстрасистолия (ВЭ), фибрилляция предсердий (ФП). С другой стороны, это нарушение ритма само вызывает дилатацию ЛП. Однако данные последних исследований показывают, что более точным маркером структурного ремоделирования ЛП является индекс объема ЛП.

Ключевые слова: ремоделирование левого желудочка, оглушение левого предсердия, сердечные аритмии, ВЭ, ФП, артериальная гипертензия.

YURAK CHAP QORINCHASI DIOSTALIK LATENT DISFUNCSIYA HOLATIDA CHAP YURAK BO'MACHASI MIYOKARDI FUNKSIONAL HOLATINI TASXISHLASH

Baratova M.S., Khamrashaev B.B.

Jamoat salomatligi va sog'liqni saqlashni boshqarish Abu Ali ibn Sino nomidagi Buxoro davlat Tibbiyot Instituti Respublika shoshilinch tibbiy yordam ilmiy markazining Buxoro filiali

✓ **Rezyume**

Garvard tibbiyot maktabi bu hodisani miokardni hayratlanarli deb atadi, bu ajoyib degan ma'noni anglatadi. Bundan tashqari, miyokardni hayratga solishning klinik ahamiyati bor-yo'qligi masalasi munozarali bo'lib qoldi, chunki hayrat paytida miyokardning kontraktilyasining pasayishi orqaga qaytariladi.

Qon bosimining ko'tarilishi gipertrofiya va dilatatsiya jarayonlarini, geometriyadagi o'zgarishlarni, sistolik va diastolik funktsiyalarni buzilishini o'z ichiga olgan chap qorincha (LV) qayta qurish rivojlanishiga olib keladi. LVdagi tarkibiy o'zgarishlar chap atriumning (LA) haddan tashqari yuklanishi va uning kengayishi bilan birga keladi, bu esa o'z navbatida ajoyib LA ga olib keladi va qorincha ekstrasistolasi (VE), atriyal kabi ritm buzilishlarini rivojlanishiga moyil bo'lgan omil hisoblanadi. fibrilatsiya (AF). Boshqa tomondan, ushbu ritm buzilishining o'zi LA dilatatsiyasini keltirib chiqaradi. Biroq, yaqinda o'tkazilgan tadqiqot ma'lumotlari shuni ko'rsatadiki, LA tarkibiy qayta qurishni aniqroq belgisi bu LA hajm indeksidir.

Kalit so'zlar: chap qorinchani qayta qurish, chap atriyalni hayratga solishi, yurak ritmining buzilishi, EE, AF, arterial gipertenziya.

Relevance

Changes in blood pressure, starting as a functional disorder, consistently lead to specific organ damage and, in the absence of timely and adequate therapy, to severe cardiovascular complications. One of the significant medical and social problems is arterial hypertension (AH). By 2025, it is predicted that the number of hypertensive patients will increase by more than 1.5 times and will amount to 1.5 billion patients in the world [1, 12, 17, 18, 23, 27]. Such as disability and premature mortality from the development of complications such as atrial fibrillation, thrombosis of the heart cavities, cerebrovascular accident, myocardial infarction, circulatory failure, etc. Heart changes that occur with arterial hypertension are the cause of the development of heart rhythm disturbances ventricular extrasystoles (VE), tachycardia, atrial fibrillation (AF). Atrial dilatation plays an important role in the development of AF. In 1975, representatives of the Harvard Medical School, led by Heyndrickx G.R., presented the results of an experimental study that examined the effect of ischemia and subsequent reperfusion on myocardial contractility. Later, other representatives of the Harvard Medical School called this phenomenon myocardial stunning, which means "stunning" [38,39]. In addition, for a long time the question of whether myocardial stunning has a clinical significance, since the decrease in myocardial contractility during stunning is reversible, remained controversial. Structural changes in the atria such as "stunnedness" or stunning of the myocardium are of particular importance for the development of tachycardia, PVC, AF [5]. A natural consequence of arterial hypertension (AH) is the formation of left ventricular hypertrophy (LVH), which leads to an increase in left ventricular (LV) rigidity and worsening of its diastolic relaxation, which leads to LV diastolic dysfunction [3,6,9]. The amount

of preload is of great importance in the diastolic function of the ventricles. The compliant ventricle is easily filled with blood, which contributes to adequate stretching and subsequent contraction of muscle fibers according to the Frank-Starling law. A "hard" ventricle is unable to receive the required volume of blood. In order to achieve stretching of the muscle fibers and provide the necessary preload, an increased filling pressure is required. As a result, the end-diastolic pressure (EDP) in the ventricle increases, which contributes to the preservation of the normal EDP and cardiac output for the time being [1,37]. The consequence of a violation of the extensibility of the ventricular myocardium is also a compensatory increase in atrial contractility, which intensively ejects at the end of the diastole the last volume of blood filling the ventricle, increasing the preload and maintaining the normal stroke volume (SV) and cardiac output. With atrial fibrillation, in the absence of a single atrial contraction, there is a significant decrease in preload, stroke volume and cardiac output [4]. LV diastolic dysfunction promotes hemodynamic overload of the left atrium, its stretching, manifestation of arrhythmic activity in the form of supraventricular rhythm disturbances - extrasystole, atrial fibrillation [14]. Back in 1964 G.K. Moe et al. came to the conclusion that any increase in the size of the left atrium increases the likelihood of developing atrial fibrillation [30]. And in 1986 M.S. Kushakovskiy described dilatation of the left atrium as a prerequisite for the inevitability of atrial fibrillation [10,11]. It is known that atrial myocardial dystrophy with their subsequent "primary" and "secondary" (retrograde) expansion create a substrate for sinus rhythm disturbances (SR). However, earlier, in 1949, E. Phillip and S. Levin reported on the possibility of developing paroxysms of tachycardia, atrial

fibrillation (AF) in people who do not have any heart disease, except for the tachyarrhythmia itself. Diagnosis of disorders of diastolic function is based mainly on the use of instrumental methods [20,21,25,26,33,34]. To assess diastolic function in a clinical setting, two approaches are used: a) assessment of active and passive characteristics of relaxation; b) analysis of the structure of diastolic filling. It is known that in hypertension, remodeling of the left ventricle (LV) develops, including the processes of hypertrophy and dilatation, changes in geometry and impairment of systolic and diastolic functions [13,26]. Structural changes in the LV are accompanied by LA overload and its dilatation, which, in turn, is a factor predisposing to the development of rhythm disturbances. On the other hand, this rhythm disturbance itself causes LA dilatation [15,17,22,28]. However, recent research data indicate that a more accurate marker of LA structural remodeling is the LA volume index (LPI) [21, 31].

In 1989. W. Manning et al. demonstrated in their studies that in most patients with persistent AF, after restoration of sinus rhythm, a phenomenon of temporary mechanical LA dysfunction was observed, characterized by the authors as the phenomenon of "stunning" or "stunned" [24]. And in subsequent studies by other authors, the phenomenon of inhibition of the function of the LA and its ear was confirmed [16, 14,21]. In 1988 I. Van Dam et al. proposed to use a combined index - the ratio of the velocities of the peaks E and A of the transmitral blood flow [35]. If relaxation of the left ventricle is impaired, the decrease in pressure in it during diastole slows down, which in turn leads to a decrease in the rate of early filling (peak E). As a result, there is an increase in the filling volume and the rate of contraction of the left atrium (peak A). In the mosaic lesion of the myocardium, there are areas without signs of mechanical activity, but with preserved basic physiological functions. Departure from this ideal geometry dictates the need for early application of diagnostic methods for the "dormant", "stunned" left atrial myocardium. Thus, the diagnosis of stunning LP in arterial hypertension with normal and latent diastolic dysfunction in the analysis of literature data allows us to conclude that currently it is insufficiently studied.

Purpose of the study: To diagnose left atrial stunning in patients with arterial hypertension with normal and latent left ventricular diastolic dysfunction. The research results were processed using the statistical processing packages Statistica, version 6.0. The research used the methods of mathematical statistics: methods of

variation statistics, frequency, variance and correlation analyzes. The significance of differences in the groups was determined using the t-test (Student's test).

Material and methods

On the basis of the regional cardiological dispensary, a retrospective study was made of 73 outpatient records of patients with essential hypertension and rhythm disturbances aged 30 to 56 years (average age 40.2 ± 2.7 years). The observation period was 6 months. Patients complained of palpitations, recurrent discomfort behind the breastbone, feeling short of breath, and destabilization of blood pressure. A Holter ECG and an ultrasound examination (ECHO KG) were performed. In order to diagnose left ventricular (LV) remodeling, the myocardium mass, myocardial mass index, and relative wall thickness index were determined. To assess the geometric model of the LV, the classification was used (normal LV geometry, concentric left ventricular remodeling - LV, concentric LV hypertrophy - eccentric LV hypertrophy). The patients were divided into 2 groups: group 1 (n = 32) with hypertension without heart rhythm disturbances. The duration of hypertension was 4.894 ± 2.21 years, in group 2 (n = 41) with hypertension and cardiac arrhythmias - tachycardia, VE, impaired repolarization of the ventricles. The duration of hypertension in this group was 5.820 ± 3.21 years. In the presented group, during the study, we identified the following variants of heart rhythm disturbances: tachycardia - 10 (24%), frequent ventricular monotopic extrasystole - 18 (44%), polytopic - 6 (33%), atrial fibrillation - 13 (32%).

The diagnosis was established on the basis of anamnestic, clinical, laboratory data, as well as the results of a functional diagnostic study, echo cardiographic examination and examination of the fundus, if necessary, consultation of a neuropathologist. Symptomatic arterial hypertension was excluded based on the results of the study of general blood, urine, biochemical parameters, and ultrasound examination of the kidneys. Among the patients studied, there were also no patients with ischemic heart disease, with signs of heart and renal failure, anemia, lung disease, diseases, thyroid gland, diabetes mellitus.

Systolic and diastolic blood pressure was measured for all subjects, echocardiographic studies were performed on the dimensions of the left atrium along the long axis and in the 2-chamber position, the transmitral flow, the thickness of the interventricular septum and the posterior wall of the left ventricle.

The primary study and the decision to enroll in the study were carried out within the first 2-3 days after contacting the clinic. During this period of time, patients did not receive drugs that could affect hemodynamics.

The studies were carried out in a polyclinic on a SANOMED-500 ultrasound machine. During echocardiography along the long axis, the end diastolic (EDV) and end systolic (ESV) volumes of the left ventricle were determined, along the long axis and in the apical 2-chamber position, the systolic volumes of the left (VLP), the size of the LP. With the help of pulse-wave Doppler, the degree of mitral regurgitation was specified. To assess the systolic function of the left ventricle, the ejection fraction (LVEF) was calculated. Violation of left ventricular diastolic function was diagnosed if people under the age of 50 had less than 55 cm/s.

Statistical processing of the obtained results was carried out using the statistical package "Statisticav.6.0". The arithmetic mean (M) and the

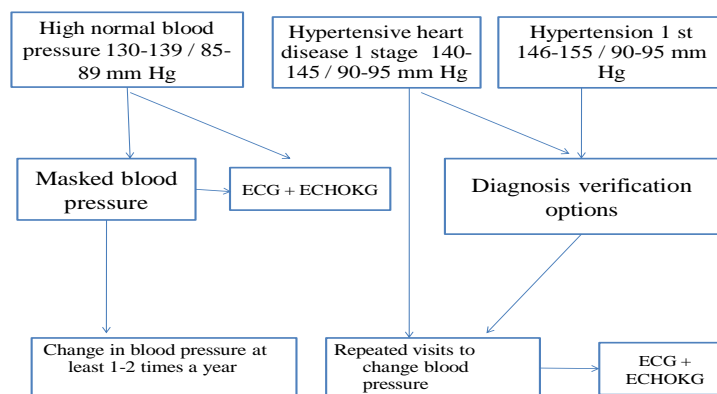
error of the mean (m) were calculated. The normality of the sample distribution was assessed by the Kolmogorov - Smirnov test.

The reliability of the differences between the values was determined using the Student's t-test with a normal distribution of the trait, with the distribution of a trait different from normal - using the nonparametric Mann - Whitney method. For the analysis of qualitative features, Fisher's exact test and χ^2 were used. Differences were considered significant at $p \leq 0.05$.

Results of the study

ECG changes were diagnosed in the first group 40.13% of cases, in the second group 47.71% of cases and in the third group 12.14% of cases, risk distribution: risk 1 - 53 people. (35.58%), risk 2 - 50 people. (33.50%), risk 3 - in 39 people. (26.17%), risk 4 - in 7 people. (4.75%). In total, changes in the analyzed ECG parameters were detected in 48.99% of cases..

Research algorithm:



The most often revealed ECG changes: incomplete blockade of the right bundle branch block - 4 people. (6%), violation of intraventricular conduction - 5 people. (7%), supraventricular

extrasystoles - 35 people. 47%, ventricular premature beats - 15 people. (21%), early repolarization of the ST segment - 5 people (7%), atrial fibrillation - 9 people (12%).

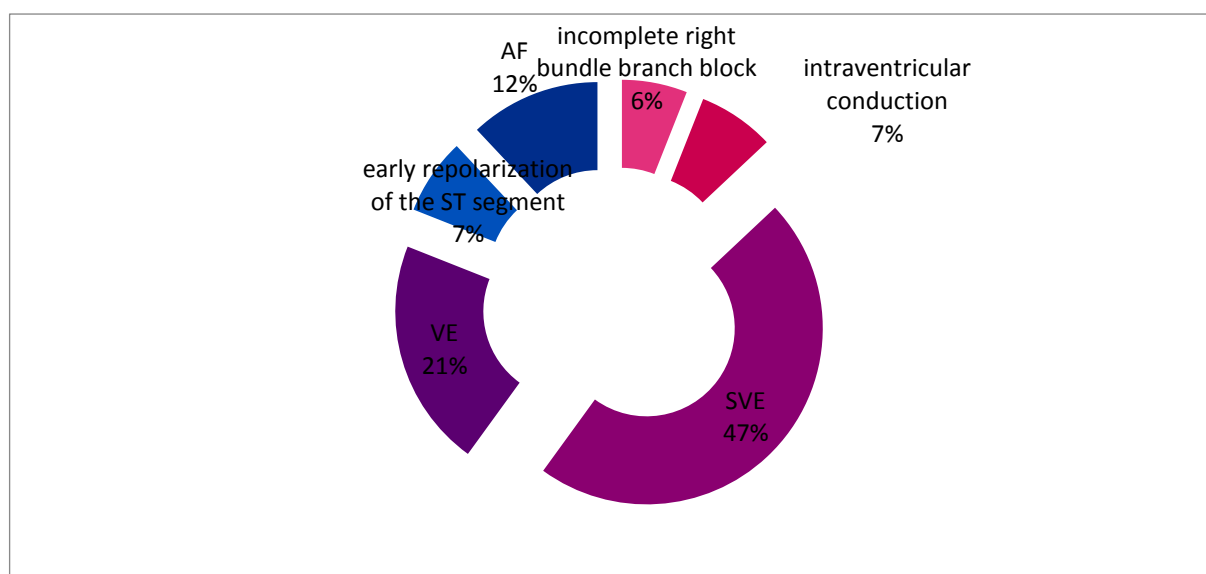


Figure 1. Changes in the indicators of conduction disturbances on the ECG in the subjects (in percentages).

In the study of echocardiography, myocardial hypertrophy was often observed along the interventricular septum of the median from 1.09-

1.12 cm - in 46 people (30.89%), basal 1.12-1.14 cm - in 28 people (18.79%), anterior-apical sections from 1.14-1.21 cm - in 58 people (38.92%), 1.21-1.3 cm along the interventricular septum and posterior wall - in 17 people. (11.41%).

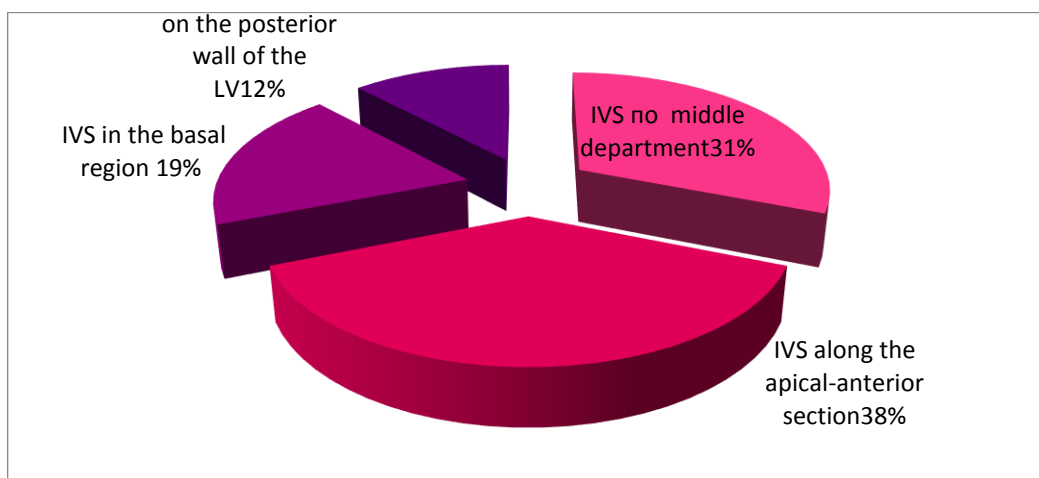
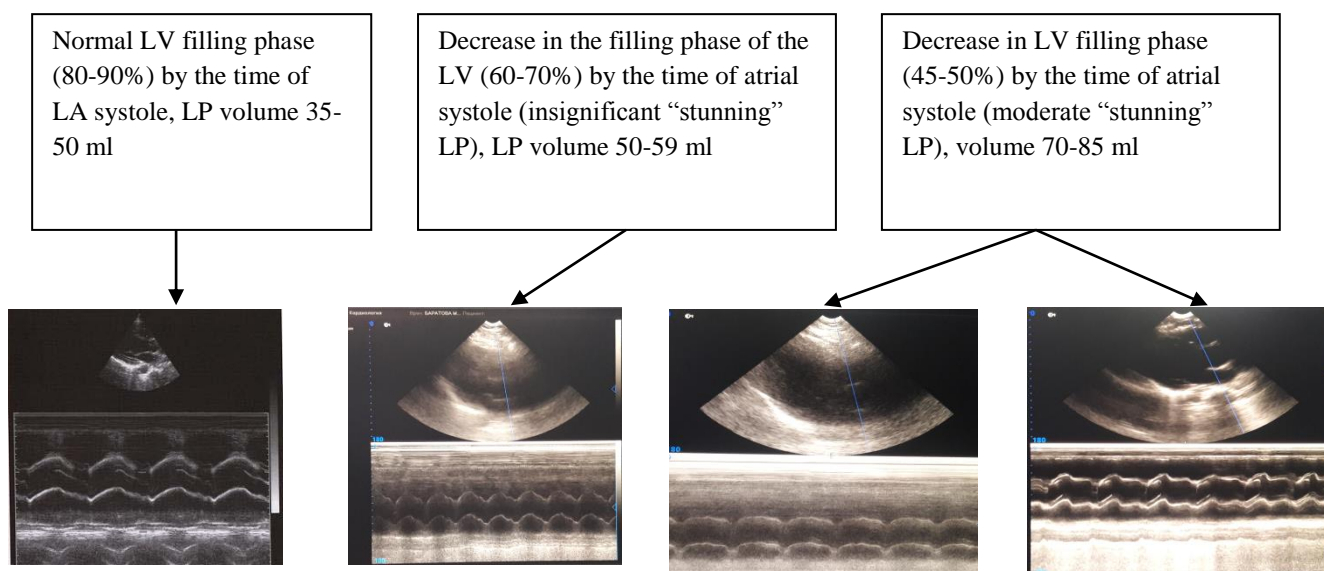


Figure 2. EchoCG indices of changes in the interventricular septum and the posterior wall of the left ventricle in the subjects.



The size and deformation of the LA closely depends on the state of the LV, the stiffness and extensibility of which during filling, as well as

contractility during systole, affect the atrial parameters (Table 1).

Hemodynamic parameters and changes in the size of the left atrium in the examined individuals

№	Study groups	1- group n=32	2- group n=41
1	IVS, mm	11,074±1,224	12,240±1,033
2	BW LV, mm	10,348±1,330	12,029±1,785
3	LP volume (ml)	41,711±3,454	46,786±3,621
4	Long axis LP	4,161±3,340	4,712±3,230
5	LVEF, %	61,256±2,372	57,468±2,282*
6	LVMI, g / m ²	98,297±4,088	138,125±4,550**
7	SBP	124,210±6,210	134,424±6,400*
8	DBP	83,860±4,420	94,125±4,240*

Note: * p <0.05, ** p <0.05 significance of differences between groups.

Early diagnosis of the study of temporary "stunnedness" - in other words, stunning left atrium of the left atrium of the 2nd and 4th chamber positions, and the size determined by the length of the heart axis.

Myocardial hypertrophy leads to an increase in the rigidity of the left ventricle (LV) and a deterioration in its diastolic relaxation, which leads to stunning (stunning) of the left atrial myocardium. Atrial contraction and their relationship to transmitral blood flow in LV hypertrophy leads to a partial absence of atrial systole (peak A) as well as to a decrease in the atrial systolic blood flow rate of less than 0.5 m / sec. A decrease in atrial blood flow velocity leads to left atrial instability and the occurrence of temporary LA stunning and its duration may be associated with the duration of the current episode of atrial fibrillation, with the size of the atria.

Conclusion

In patients, the electrocardiogram in 39.5% reveals changes associated with stunning of the left atrium, leading to impaired intraventricular conduction, early repolarization syndrome and cardiac arrhythmias (tachycardia, extrasystoles). Remodeling was observed, leading to hypertrophy of certain parts of the myocardium, and in 31.5% of cases, the concentric type of hypertrophy occurs, which is considered the most unfavorable in prognostic terms, which requires more careful monitoring of this category of patients. The examined patients showed early signs of left ventricular diastolic dysfunction, diastolic dysfunction is mainly represented by hemodynamic disorders and early stunning of the left atrium (67%). It is certain that with atrial contraction and their relation to the transmitral blood flow in LV hypertrophy leads to a partial absence of atrial systole (peak A) as well as to a decrease in the speed of atrial systolic blood flow less than 0.5 m/sec.

LIST OF REFERENCES:

1. Arterial hypertension among persons aged 25-64: prevalence, awareness, treatment and control. Based on research materials ESSE / S.A. Boytsov, Yu.A. Balanova, S.A. Shalnova [et al.] // Cardiovascular therapy and prevention. - 2014. - No. 13 (4). - P. 4-14.
2. Ataeva M., Jarylkasynova G., Baratova M. Assessment of heart rhythm disorders at left atrial stunning at early stages of left ventricular modeling//Journal of Critical Reviews, 7 (4), 1695-1699. doi:10.31838/jcr.07.04.277.
3. Baratova M. S. Respiratory Viral Infections in the Formation of Left Atrial Stunning and Its Early Diagnostics // American Journal of Medicine and Medical Sciences 2020, 10(4): 269-272. DOI: 10.5923/j.ajmms.20201004.18
4. Bockeria L.A., Golukhova E.Z. (ed.) Clinical cardiology: diagnosis and treatment. In 3 volumes. Moscow: NTSSKh im. A.N. Bakuleva RAMS; 2011. T 3.
5. Belenkov Yu.N., Mareev V.Yu. Cardiovascular continuum. Heart failure. - 2002. - T. 3 (1). - S. 7-11.
6. Belenkov Yu.N., Agmanova E.T. Diastolic function of the heart in patients with chronic heart failure and methods of diagnosing its disorders using tissue myocardial Doppler echocardiography. Cardiology. 2003; 11: 58-66.
7. Gubareva, I.V. Study of the relationship between myocardial stress and natriuretic peptides in patients with different types of left ventricular diastolic dysfunction [Text] / I.V. Gubareva, N.N. Kryukov // Bulletin of the Volgograd State Medical University. - 2014. - No. 1 (49). - S. 108-109.
8. Gubareva, I.V. Method for the diagnosis of left ventricular diastolic dysfunction in patients with arterial hypertension [Text] / I.V. Gubareva // Bulletin of the Samara Scientific Center of the Russian Academy of Sciences. - 2014. - T. 16, No. 5/4. - S. 1266-1268.
9. Gromyko T.Yu., Saiganov S.A. Left atrial remodeling in patients with atrial fibrillation with various methods of restoring sinus rhythm. I.I. Mechnikov. - 2017. - T. 9. - No. 2. - S. 51-59.
10. Kushakovskiy, M.S. Diastolic function of the left ventricle and the size of the left atrium in patients with paroxysms of atrial fibrillation / M. S. Kushakovskiy, I. I. Yakubovich // Therapeutic archive. - 1995. - No. 6. S. 2125
11. Kushakovskiy M.S. Isolated atrial fibrillation. Arrhythmology Bulletin. -2002. - 28. -- S. 9-11.
12. Kryukov, N.N. Duplex scanning of the brachiocephalic trunk of patients with arterial hypertension with diastolic dysfunction of the left ventricle / N.N. Kryukov, I. V. Gubarev // Bulletin of the Samara Scientific Center of the Russian Academy of Sciences. - 2011. - T. 13, No. 1/7. - S. 1717-1720.
13. Miller O.N., Skurikhina O.N., Gusyatnikova T.A. et al. Angiotensin-converting enzyme inhibitors in myocardial remodeling in patients with arterial hypertension and atrial fibrillation // Russian Journal of Cardiology. - 2007.T. 5. - S. 74-78.
14. Machine T.V., Golukhova E.Z. Diastolic dysfunction of the left ventricle in patients with atrial fibrillation: pathogenetic mechanisms and modern ultrasound methods of assessment (analytical review) // Creative Cardiology 2014, No. 4.P.43-52.

15. Radha B., Saiganov SA, Gromyko T.Yu. Atrial fibrillation in patients with myocardial infarction of lower localization. Bulletin of the North-Western State Medical University 2015; 7 (1): 46-51.
16. Strakhova K.V., Velikova I.V., Mazurov V.V. Stanning of the atria as a stage of their reverse remodeling after restoration of sinus rhythm in patients with idiopathic atrial fibrillation // Herald of arrhythmology. - 2010. - No. 62. - S.37-40.
17. Chazova, I.E. Arterial hypertension: from A.L. Myasnikova to the present day / I.E. Chazova // Consilium Medicum. - 2014. - No. 12. - P. 5-9.
18. Epidemiology of arterial hypertension in Russia. Results of the Federal Monitoring 2003-2010 / R.G. Oganov, T.N. Timofeeva, I.E. Koltunov [et al.] // Cardiovascular therapy and prevention. - 2011. - No. 1. - P. 9-13.
19. Aldhoon B., Melenovsky V., Peichl P., et al. New insights into mechanisms of atrial fibrillation. *Physiol. Res.* 2010; 59 (1): 1-12.
20. Abhayaratna W.P., Fatema K., Barnes M.E., et al. Left atrial reservoir function as a potent marker for first atrial fibrillation or flutter in persons > or =65 years of age. *Am J Cardiol* 2008; 101: 1626-1629.
21. Bijnens B.H., Cikes M., Claus P. et al. Velocity and deformation imaging for the assessment of myocardial dysfunction. *Eur. J. Echocardiogr.* 2009; 10: 216-26.
22. Cha Y.M., Redfield M.M., Shen W.K. et al. Atrial fibrillation and ventricular dysfunction. *Circulation.* 2004; 109: 2839-43.
23. ESC Guidelines on the diagnosis and treatment of peripheral artery diseases // *Eur. Heart Journal.* – 2011. – Vol. 32. – P. 2851–2906.
24. Manning W., Silverman D., Keighley C et al. Transesophageal echocardiographically facilitated early cardioversion from atrial fibrillation using short-term anticoagulation: Final results of a prospective 4.5 year study. // *J. Am. Coll. Cardiol.* - 1995. - V. 25, - P. 1354-1361..
25. Gupta S., Matulevicius S.A., Ayers C.R., et al. Left atrial structure and function and clinical outcomes in the general population. *Eur Heart J* 2013; 34: 278-285.
26. Gabriel R.S., Klein A.L. Modern evaluation of left ventricular diastolic function using Doppler echocardiography. *Curr. Cardiol. Rep.* 2009; 11: 231-8.
27. Kearney, P.M. Global burden of hypertension: analysis of worldwide data / P.M. Kearney, M. Whelton, K. Reynolds // *Lancet.* – 2005. – Vol. 365. – P. 217– 223.
28. Lupu S., Mitre A., Dobreanu D. Left atrium function assessment by echocardiography - physiological and clinical implications. *Med. Ultrason.* 2014; 16 (2): 152-9.
29. Legedz L., Rial M.O., Lantelme P. Markers of cardiovascular remodeling in hypertension. *Arch. Mal. Coeur. Vaiss.* 2003; 96 (7-8): 729-733.
30. Moe G.K., Rheinboldt W.C., Abildskov J.A. A computer model of atrial fibrillation. *Am. Heart J.* 1964; 67: 200-20.
31. Mori M., Kanzaki H., Amaki M. Impact of reduced left atrial functions in diagnosis of paroxysmal atrial fibrillation: results from analysis of time-left atrial volume curve determined by two-dimensional speckle tracking. *J. Cardiol.* 2011; 57: 89-94.
32. Okcun B., Yigit Z., Arat A., Baran T. et al. Stunning of the left atrium after conversion of atrial fibrillation: predictor for maintenance of sinus rhythm? // *Echocardiography* 2005; 22(5):402 .
33. Rosenberg M.A., Manning W.J. Diastolic dysfunction and risk of atrial fibrillation. A mechanistic appraisal. *Circulation.* 2012; 126: 2353-62.
34. Rosenberg M.A., Gottdiener J.S., Heckbert S.R. et al. Echocardiographic diastolic parameters and risk of atrial fibrillation: the cardiovascular health study. *Eur. Heart J.* 2012; 33: 904-12.
35. Van Dam I., Fast J., de Boer T., Hopman J., Van Oort A., Heringa A., Alsters J., Van Der Werf T., Daniels O. Normal diastolic filling patterns of the left ventricle *Eur. Heart J.* 1988; 9: 165-71.
36. Zapolski T., Wysokinski A. Stunning of the left atrium after pharmacological cardioversion of atrial fibrillation. // *Kardiol. Pol.* 2005; 63: 3: 254-62.
37. Zile M.R., Brutsaert D.L. New in diastolic dysfunction and diastolic heart failure. Part 1: diagnosis, prognosis, and measurements of diastolic function. *Circulation.* 2002; 105: 1387-93. Nagarakanti R., Ezekowitz M. Diastolic dysfunction and atrial fibrillation. *J. Interv. Card. Electrophysiol.* 2008; 22: 111-8.
38. Heyndrickx G.R., Millard R.W., McRitchie R.J. et al. Regional myocardial functional and electrophysiological alterations after brief coronary artery occlusion in conscious dogs. *J. Clin. Invest.* 1975. Vol. 56. P. 978-985.
39. Braunwald E. The Stunned Myocardium: Prolonged, Postischemic Ventricular Dysfunction. *Circulation.* 1982. Vol. 66. P. 1146-1149.

Entered 09.03.2021