

# CLINICAL PICTURE OF VESTIBULAR SCHWANNOMAS IN A SERIES OF 106 PATIENTS MANAGED WITH DIFFERENT TREATMENT METHODS

1Ergashev J., 2Santos S., 1Rasulova N., 1Yakubov M., 1Salomov K.

1 Tashkent Pediatric Medical Institute, 2 University of Santiago de Compostela.

## ✓ Resume,

The authors were a retrospective study of 106 patients with vestibular schwannoma (VS) which was conducted in the population of Galicia, who visited the University Hospital Santiago de Compostela from February 21, 1992 to March 3, 2014. In this study, we included only VS cases, and most of them were diagnosed by MRI with enhanced gadolinium. As exclusion criteria, we used tumors separately from VS or cases of CPA tumors of unknown origin. According to the authors, the clinical manifestations of the tumor vary greatly and include unilateral high-frequency sensorineural hearing loss, tinnitus, imbalance, pressure in the ear, earache, sometimes dizziness, instability, etc. The deterioration of clinical signs often associated with a tumor growth. The most common symptom at the time of diagnosis is hearing loss. Type of hearing loss is a neurosensory high frequency hearing loss with an oblique audiometric configuration.

Keywords: hearing loss, neurosensory high-frequency hearing loss with oblique audiometric configuration, hearing loss, tinnitus, imbalance, pressure in the ear, earache, dizziness.

# КЛИНИЧЕСКАЯ КАРТИНА ВЕСТИБУЛЯРНЫХ ШВАННОМ У 106 БОЛЬНЫХ, ПОД РАЗЛИЧНЫМИ МЕТОДАМИ ЛЕЧЕНИЯ

1Эргашев Ж.Д., 2Сантос С., 1Расулова Н.А., 1Якубов М.М., 1Саломов К.М.

1 Ташкентский педиатрический медицинский институт,  
2 Университет Сантьяго-де-Компостела, Сантьяго-де-Компостела, Испания

## ✓ Резюме,

Авторами было ретроспективное исследование 106 пациентов с вестибулярной шванномой (ВШ) которое было проведено среди популяции Галисии, посещавших Университетскую клинику Сантьяго-де-Компостела в период с 21 февраля 1992 года по 3 марта 2014 года. Исследованию исключительно были включены ВШ, которые были диагностированы с помощью контрастной МРТ. Критериями исключения были все другие опухоли, не являющие ВШ, или опухоли неизвестного происхождения.

По мнению авторов, клинические проявления ВШ сильно варьируют, таких как односторонняя высокочастотная нейросенсорная тугоухость, шум в ушах, нарушение равновесия, чувство давления в ухе, оталгия, головокружение, боль в области лица, парезы и гемипарезы лицевого нерва и т.д. Ухудшение состояния больных, часто были связаны с увеличением размера опухоли. Наиболее распространенным симптомом на момент постановки диагноза было высокочастотная тугоухость с наклонной аудиометрической конфигурацией.

Ключевые слова: потери слуха, нейросенсорная тугоухость, высокочастотная тугоухость, шум в ушах, нарушение равновесия, чувство давления в ухе, оталгия, головокружение.

# ТУРЛИ УСУЛЛАРДА ДАВОЛАНАЁТГАН 106 НАФАР ВЕСТИБУЛЯР ШВАННОМА ТАШХИСИ ҚЎЙИЛГАН ПАЦИЕНТЛАР МИСОЛИДА ВЕСТИБУЛЯР ШВАННОМАНИНГ КЛИНИК МАНЗАРАСИ

1Эргашев Ж.Д., 2Сантос С., 1Расулова Н.А., 1Якубов М.М., 1Саломов К.М.

1 Тошкент педиатрия тиббиёт институти, Ўзбекистон  
2 Сантьяго де Компостела Университети, Испания

## ✓ Резюме,

Ушбу иш Испаниянинг Сантьяго де Компостела Университети тиббиёт Клиникасига Галисия провинциясидан Вестибуляр Шваннома (ВШ) таъхиси билан 02.21.1992 - 03.03.2014 йиллари даволанган 106 нафар беморларни ретроспектив ўрганиш натижаларини қисман ўз ичига олади. Авторлар ушбу ишга фақат ВШ билан оғриган пациентларни киритиб ривожланиш сабаби номаълум бўлган ўсмаларни истисно қилишган. ВШ таъхиси гадолин контрастли МРТ билан амалга оширилган.

Авторларга кўра ВШ турли клиник белгилар билан намойён бўлиши мумкин. Бу белгилар: юқори частотали нейросенсор эшитиш пастлиги, қўлоқда шовқинлар, мувозанат бузулишлари, қўлоқда босим борлиги ҳисси, қўлоқ оғриши, бош айланиши, юз нервини парези, параличи ва ҳ.к.з. Беморларда энг кўпроқ топилган даслабки белги бу эшитишнинг пасйиши белгиси авторлар томонидан эътироф этилган. Беморлардан клиник белгиларни ва уларни ахволини оғирлашиши кўпчилиқ ҳолларда ВШ ўлчамларини ортиб бориши билан боғлиқлиги аниқланган.

Калит сўзлар: юқори частотали эшитув пастлиги, қия тушиб борувчи аудиометрик конфигурация, қўлоқда шовқинлар, мувозанат бузулиши, қўлоқ ичиди босим ҳисси, қўлоқ оғриши, бош айланиши.

## Relevance

Vestibular schwannoma (VS) or Acoustic neurinoma (AN) is a benign tumor arising of Schwann cells

forming the myelin sheath of the vestibulocochlear nerve (VN). "De duro quodam corpusculo, nervio auditorio adherente" - were the first postmortem descriptions made for VS in 1777, by Eduard Sandiford - Professor of

Pahology in Leiden, in his book called "Anatome infantis cerebro destitute" [1,2,3].

The cause of VS is unknown. However, Cushing (1917) and Revilla (1948) believed trauma was a plausible explanation, as some observations apparently associated occipital traumawith tumors of the cerebellopontine angle (CPA) [3-5].

According to some other authors, VS related symptoms are sometimes exacerbated during pregnancy has elicited the hypothesis that hormonal mechanisms may be involved in the genesis or progression of these tumors. A hereditary component is reasonably unlikely, except in the unquestionably inherited cases of schwannoma that present as part of the complex of neurofibromatosis type [2-5].

The clinical presentations of a VS is highly variable and includes unilateral high frequency sensoneural hearing loss, tinnitus, disequilibrium, pressure in the ear, otalgia, and occasionally vertigo, which result from pressure exerted by the tumor upon the cochlear and vestibular portions of the eighth cranial nerve. But the hearing loss is the most common finding, occurring in more than 95% of patients over the course of this disease [2,3].

Over the last decade, incidence of VS appears to be increasing. According to data from Denmark based upon an established comprehensive VS tumor registry suggest an increase from 7.8 to 12.4 cases per million from 1976to 1995. As incidence appears to be increasing, tumor size at time of diagnosis is falling, while median age at diagnosis remains relatively static [3,4].

The VS is benign and usually grows quite slowly [1-10]. However, as VS grows, it compresses the vestibulocochlear or both vestibulocochlear and facial nerve in internal acoustic canal and affects the hearing, balance and facial function. Therefore, usually it causes unilateral or asymmetric hearing loss, tinnitus, and loss of balance from simple unsteadiness, up to serious vertigo [2-5].

### Objective

The aim of the present study was to discuss the initial signs of VS and to evaluate the symptoms and signs as well as their correlation with the tumor extension over the time. Our analysis based on subjective disturbances against objective condition of the patient and symptomatology against to results of audiologic tests and VS size.

The sudden hearing loss occurs in about 25% of patients with VS. However, because VS is a rare condition, sudden hearing loss attributable to an acoustic tumor occurs in only 1-5 percent of patients with sudden hearing loss, as there are many more common causes. Even a sudden hearing loss with complete recovery can be caused by a VS.35. The mechanism of hearing loss is related to the direct compression of the cochlear nerve. Hearing loss occurs in VS patients as a symptom may be of several years' duration prior to diagnosis.

In some cases the tumor growth may interfere with the facial nerve causing facial numbness, or it may also affect the motor fibers of the facial nerve causing facial weakness or paralysis on the ipsilateral side. In case, if the tumor becomes larger and larger it may prolapse into CPA like an ice cream cone, and it will eventually compress against nearby the important brain structures like the brainstem and the cerebellum which makes the VS life-threatening (Fig.1).

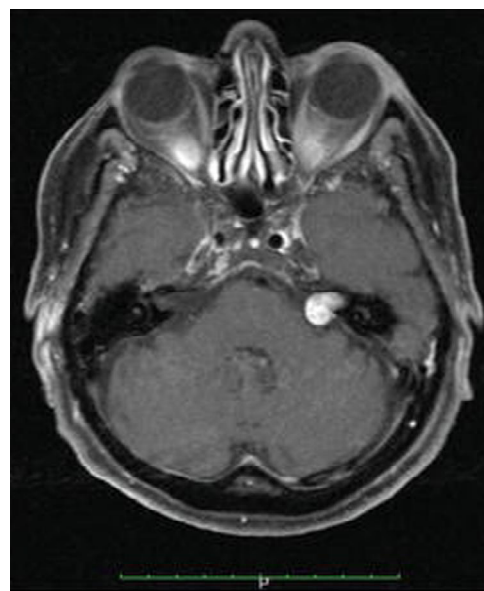


Fig. 1. Contrast enhanced axial and coronal T1-weighted MRI showing small VS resembling an ice cream cone in the left cerebellopontine angle.

Therefore, the clinical presentation may depend on location and size of the VS. The majority of cases the presenting symptom of VS is a hearing loss. However, the complaint making the patient to come to the hospital could be different [3].

Many patients, especially old patients do not pay attention to hard of hearing, but they concern either ringing in the ear or balance problems. At the diagnostic stage otolaryngologists perform audio-vestibular tests and usually reveal additional signs like hearing loss and symptoms of compression of other cranial nerves [2-5].

### Patients and methods

One hundred seven (106) patients with Vestibular Schwannoma (VS) underwent a retrospective study which has been implemented in the Galicia population which attended Santiago de Compostela University Hospital from the period between February 21, 1992 and March 03, 2014.

In this study, we have included only cases of VS and most of which were diagnosed by the means of gadolinium-enhanced MRI. As criterions of exclusion we have used the tumors apart from a VS or cases of CPA tumors of unknown origin.

Among the studied cases, there was 1 (0, 92%) young male, at the age of 36, who was diagnosed with a bilateral VS due to Neurofibromatosis Type II (NF2). In spite of knowing the clear distinct origin of the NF2, we have included this patient as a clinical presentation and the nature of the tumor was absolutely the same.

### Results

#### Initial symptoms

First of all, we have revealed the primary symptoms of VS which brought the patient to the physician (Table 7). In the majority of cases, 68 (64.1%), the primary symptom of a VS was hearing loss in the affected ear. The second major presenting symptom of a VS was tinnitus.

The first sign of a VS in 24 (22.1%) of the patients was the complaint of having tinnitus (Table 1).

Table 1.

**Distribution of patients regarding the type of presenting symptoms of VS**

Primary sign of VS	Number of patients	Percentage
Hearing loss	68	64,1%
Tinnitus	24	22, 1%
Vertigo	9	8, 3%
Unsteadiness	4	3, 7%
Dizziness	1	0,9%
Total	106	100,0%

#### Symptoms at the time of diagnosis

Apart from the symptoms of presentation reported by patients, there were additional symptoms found at the oto-neurologic examination which immediately brought about their diagnosis.

In 11 (16.1%) out of 68 (63.2%) patients, the hearing loss was the only presenting symptom of a VS and there were no any other symptoms at the time of diagnosis. But in 54 (59.0%) of the patients with hearing loss, the tinnitus and vestibular symptoms presented were associated with

hearing loss. Only in one case (0.94%) out of 106 patients, did the tinnitus purely present a VS at the pretreatment stage. In contrast, in 23 (21.6%) cases of hearing loss, vestibular and other symptoms, were associated secondly to tinnitus. The cases of vertigo and unsteadiness never presented as an only sign of a VS and the patients were always associated with either symptom. But in the case of one (0.94%) patient, the dizziness was purely presented as VS. The detailed clinical symptoms and their association can be seen in Table 8.

Table 2.

**Distribution of presenting symptoms (which brought the patient to a physician) and symptoms found at the time of diagnosis of a VS**

Presenting symptom	Additional symptoms found at the time of diagnosis	
<b>Hearing loss (68)</b>	Only hearing loss (11)	
	Tinnitus (40)	Only tinnitus (26)
		Instability and/or vertigo (10)
		Hypoesthesia in Ramsay-Hunt area (2)
		Instability and hypoesthesia in R-H area (1)
		Vertigo and facial palsy (1)
	Vertigo, dizziness and/or instability (14)	Only vertigo, dizziness and/o instability (13)
		Dysphonia (1)
	Other: earache (1), pain in hemifacial area (1) and lack of speech indelibility (1).	
<b>Tinnitus (24)</b>	Only tinnitus (1)	
	Hearing loss (19)	Only hearing loss (18)
		Headache (1)
	Other: vertigo (1), instability (1), plugged ear (1) and dizziness, nausea and vomiting (1)	
<b>Dizziness (1)</b>	Only dizziness (1)	
<b>Instability (4)</b>	Hearing loss (1)	
	Hearing loss, dizziness and loss of consciousness (1)	
	Tinnitus (1)	
	Clumsiness of right hemisphere and facial paresis (1)	
<b>Vertigo (9)</b>	Hearing loss (6)	Only hearing loss (3)
		Instability (1), tinnitus (1) and hypoesthesia in Ramsay-Hunt area (1)
	Tinnitus (2)	
	Instability (1)	

### Localization of VS

Regarding the localization of a tumor, there were, in general, 25 (23.6%) patients who presented with an extracanalicular VS, 41 (38.7%) who presented with an intracanalicular VS, and 40 (37.7%) patients who presented with an intra-extracanalicular VS. Among the

patients with an intracanalicular VS, there were 27 (65.8%) females and 14 (34.1%) males. In a group of patients with intra-extracanalicular VS, there were 19 (47.5%) females and 21 (52.5%) males. Distribution of patients regarding the localization of VS illustrated in Table3.

Table 3.

**Distribution of VS patients regarding gender and localization of a VS**

Patients			Localization of VS			Total
			Extracanalicular	Intracanalicular	Intra-extracanalicular	
Gender	Female	Number of gender	11(19,3%)	27(44,4%)	19(33,3%)	57
		% of affected side	44,0%	65,9%	47,5%	53,8%
	Male	Number of gender	14 (28,6%)	14(28,6%)	21(42,9%)	49
		% of affected side	56,0%	34,1%	52,5%	46,2%
Total		Number of gender	25(23,6%)	41(38,7%)	40(37,7%)	106
		% of affected side	100%	100%	100%	100%

In order to know if there is any correlation between the localization of VS and the gender of the patients, we have applied the Chi-squared test which didn't show statistical significance (p-value 0.09).

The following plotted graph illustrates the frequency of VS related symptoms and information regarding the localization of VS.

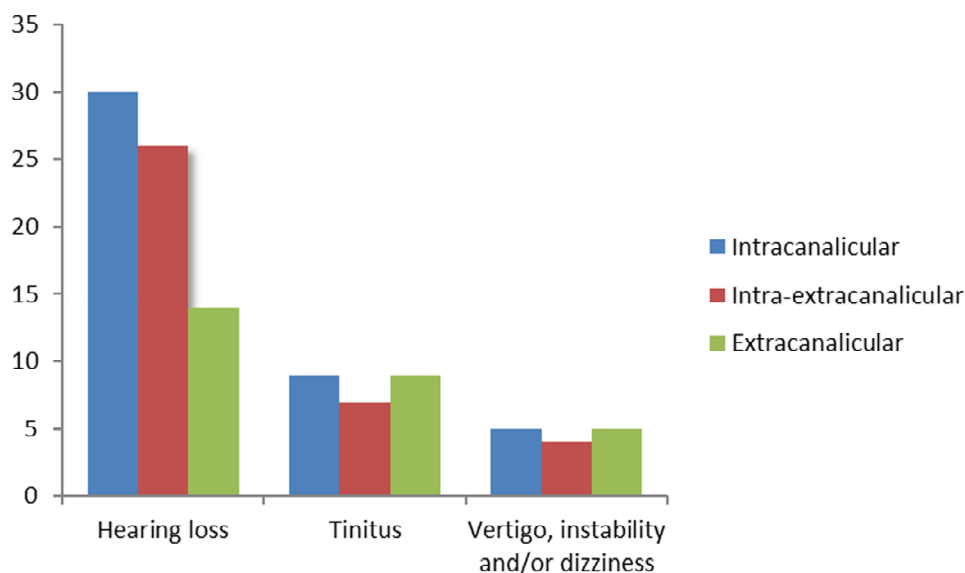


Figure 2. Distribution of presenting symptoms regarding the localization of the tumor

The plotted graph above shows a visual relationship between localization and primary symptoms of VS and the applied two tailed Pearson and Spearman test equally showing the significant relationship between localization and initial symptoms (p=0.01).

### Discussion

In general, the primary signs of a VS can be otologic, vestibular, neurologic and neurosurgical. The most common presenting otologic symptoms of VS are considered to be hearing loss.243-246 In our series, also, there are 68 (64.1%) patients who complained of hearing

loss as a presenting symptom of VS. Most literature reviewed is in agreement that tinnitus is the second most common presenting symptom of VS. 240-246

In our series, there were 24 (22.6%) patients who presented with VS as a first sign, and 43 (40.5%) patients who presented with tinnitus and with the other otologic or vestibular symptoms. Although, all 24 patients presented with tinnitus as a first sign, with a diagnostic PTA, patients presented with hearing loss in either level. Martin (Birmingham, 2013) has investigated 730 patients with VS, and among them in 70% of the cases, patients were found with tinnitus as a presenting symptom, and in 58.0% of patients, tinnitus was an accompanying symptom. In

our series, there is only one patient (0.9%) who presented with tinnitus as a sole-reported complaint. Bakkouri (France, 2009) found that 4.0% of the patients with VS showed the symptom of tinnitus alone.

### Conclusion

The clinical presentations of a VS is highly variable and includes unilateral high frequency sensorineural hearing loss, tinnitus, disequilibrium, pressure in the ear, otalgia, and occasionally vertigo, unsteadiness etc. Deterioration of clinical signs frequently related with tumor grows. The most common presenting symptom at the time of diagnosis is the hearing loss. The type of hearing loss is the sensorineural high-frequency hearing loss with the sloping audiometric configuration.

### REFERENCES:

1. Sandifort E. Observations anatomicopathologicae // Lugduni Batvarorum. - 1777; pp 116-120.
2. Thapa P., Shahi S., Jha RK., Shrestha D., Vestibular Schwannoma: An Experience in a Developing World //World J Oncol. 2019; 10(2): pp118-122.
3. Ergashev J.D., Epidemiological and Evolutionary study of Vestibular Schwannoma after different types of treatment. //PhD-thesis.; 2014. Available from: <http://hdl.handle.net/10347/10618>
4. Hughes M, Skilbeck C, Saeed S, Bradford R. Expectant management of vestibular schwannoma: a retrospective multivariate analysis of tumor growth and outcome. // Skull Base. 2011; 21(5): pp 295-302.
5. Ahsan S. F., Bojrab D., Standring R. Partial Hearing Preservation after Translabyrinthine Vestibular Schwannoma Resection: Case Report and Review of the Literature //Journal of neurological surgery reports. 2015; 76(02): pp 211-215.
6. Pinna MH, Bento RF, Neto RV. Vestibular schwannoma: 825 cases from a 25-year experience. // Int Arch Otorhinolaryngol. 2012; 16(4): pp 466-475.
7. Zou J, Hirvonen T. "Wait and scan" management of patients with vestibular schwannoma and the relevance of non-contrast MRI in the follow-up. //J Otol. 2017;12(4):pp 174-184.
8. Coughlin AR, Willman TJ, Gubbels SP. Systematic Review of Hearing Preservation After Radiotherapy for Vestibular Schwannoma. // Otol Neurotol. 2018; 39(3): pp273-283.
9. Dayal M, Perez-Andujar A, Chuang C, Parsa AT, Barani JJ. Management of vestibular schwannoma: focus on vertigo. // CNS Oncol. 2012; 2(1): pp 99-104.
10. Warade A, Chawla P, Warade A, Desai K. Contralateral hearing loss and facial palsy in an operated case of vestibular schwannoma-Case report. // Int J Surg Case Rep. 2016; pp 29:47-50.

Entered 09.09. 2019