New Day in Medicine
Новый День в Медицине
NDM

TIBBIYOTDA YANGI KUN

Ilmiy referativ, marifiy-ma'naviy jurnal



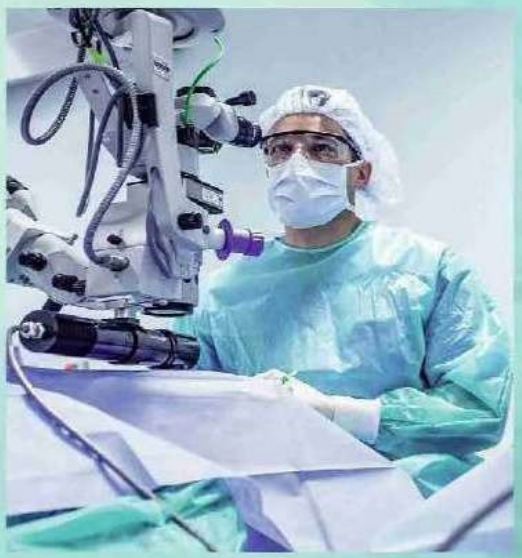

AVICENNA-MED.UZ

ISSN 2181-712X.
EiSSN 2181-2187

7 (69) 2024

ТИББИЁТДА ЯНГИ КУН
НОВЫЙ ДЕНЬ В МЕДИЦИНЕ
NEW DAY IN MEDICINE

Илмий-рефератив, маънавий-маърифий журнал
Научно-реферативный,
духовно-просветительский журнал

УЧРЕДИТЕЛИ:

БУХАРСКИЙ ГОСУДАРСТВЕННЫЙ МЕДИЦИНСКИЙ ИНСТИТУТ
ООО «ТИББИЁТДА ЯНГИ КУН»

Национальный медицинский исследовательский центр хирургии имени А.В. Вишневского является генеральным научно-практическим консультантом редакции

Журнал был включен в список журнальных изданий, рецензируемых Высшей Аттестационной Комиссией Республики Узбекистан (Протокол № 201/03 от 30.12.2013 г.)

7 (69)

2024

июль

www.bsmi.uz
https://newdaymedicine.com E: ndmuz@mail.ru
Тел: +99890 8061882

Received: 20.04.2024, Accepted: 02.07.2024, Published: 10.07.2024

UDC:616.216.1-002.2-036.2

PEDIATRIC ASPECTS OF TREATMENT OF CHRONIC RHINOSINUSITIS USING MODERN LOW FREQUENCY ULTRASOUND

Shodieva M.B. https://orcid.org/0000-0001-7272-7418
Nurov U.I. https://orcid.org/0009-0003-3955-6364

Bukhara State Medical Institute named after Abu Ali ibn Sina, Uzbekistan, Bukhara, st. A. Navoi. 1
Tel: +998 (65) 223-00-50 e-mail: info@bsmi.uz

✓ ***Resume***

This article discusses current understanding of chronic inflammation of the paranasal sinuses in school-age children, known as chronic rhinosinusitis (CRS). The article provides information on the treatment of chronic rhinosinusitis in school-age children using the Fotek AK-101 device using a chloride solution sodium 0.9% structure.

Key words: chronic rhinosinusitis, low-frequency ultrasound, cavitation, diagnosis, treatment efficacy, school-age children, local antibacterial drugs, Fotek AK-101

ПЕДИАТРИЧЕСКИЕ АСПЕКТЫ ЛЕЧЕНИЯ ХРОНИЧЕСКОГО РИНОСИНУСИТА С ПОМОШЬЮ СОВРЕМЕННОГО НИЗКОЧАСТОТНОГО УЛЬТРАЗВУКА

Шодиева М.Б. https://orcid.org/0000-0001-7272-7418
Нуров У.И. https://orcid.org/0009-0003-3955-6364

Бухарский государственный медицинский институт имени Абу Али ибн Сины, Узбекистан, г. Бухара, ул. А. Навои. 1 Тел: +998 (65) 223-00-50 e-mail: info@bsmi.uz

✓ ***Резюме***

Данная статья обсуждает актуальные представления о хроническом воспалении околоносовых пазух у детей школьного возраста, известном как хронический риносинусит (ХРС). В статье представлена информация о лечение хронического риносинусита у детей школьного возраста при помощи аппарата Фотек АК-101 с использованием раствора хлорида натрия 0,9 % структуре.

Ключевые слова: хронический риносинусит, низкочастотный ультразвук, кавитация, диагностика, эффективность лечения, дети школьного возраста, местные антибактериальные препараты, Фотек АК-101

SURUNKALI RINOSINUSITNI ZAMONAVIY PAST CHASTOTALI ULTRATOVUSH YORDAMIDA DAVOLASHNING PEDIATRIK ASPEKTLARI.

Shodieva M.B. https://orcid.org/0000-0001-7272-7418
Nurov U.I. https://orcid.org/0009-0003-3955-6364

Abu Ali ibn Sino nomidagi Buxoro davlat tibbiyot instituti, O‘zbekiston, Buxoro, st. A. Navoiy. 1
Tel: +998 (65) 223-00-50 e-mail: info@bsmi.uz

✓ ***Rezyume***

Ushbu maqolada surunkali rinosinusit (SRS) deb nomlanuvchi maktab yoshidagi bolalarda paranazal sinuslarning surunkali yallig'lanishi haqida hozirgi tushuncha muhokama qilinadi. Maqolada 0,9% li Natriy xlorid eritmasi va Fotek AK-101 ultratovushli qurilmasi yordamida maktab yoshidagi bolalarda surunkali rinosinusitni davolash haqida ma'lumot berilgan.

Kalit so'zlar: surunkali rinosinusit, past chastotali ultratovush, kavitatsiya, tashxis, davolash samaradorligi, maktab yoshidagi bolalar, mahalliy antibakterial preparatlar, Fotek AK-101

Relevance

Rhinosinusitis (RS) is an inflammatory disease of the mucous membrane of the nasal cavity and paranasal sinuses (SNS), which has a multifactorial etiology. Today, the problem of MS is undoubtedly one of the most pressing in otorhinolaryngology . Over the last decade, the incidence has increased 3 times, and the number of hospitalizations for this reason increases annually by 1.5-2% [Svistushkin V 2006]. According to various authors, MS in one form or another affects from 5 to 15% of the adult population and about 5% of children [3, 4]. Due to the relevance of the topic under discussion, there is a need to clarify some definitions and terms. In the European document on the treatment of MS and nasal polyps (EP3OS, 2007), rhinosinusitis is defined as inflammation of the nasal mucosa and SNP, characterized by two or more symptoms, one of which is nasal congestion or nasal discharge, often combined with headache/facial pain in the projection SNP and impairment or loss of smell. Additional (minor) signs can be considered: pain in the projection of the upper teeth, bad breath, general fatigue, low-grade fever, cough, ear pain.

Classifications of rhinosinusitis

According to domestic methodological recommendations [E. Araujo 2003], there are:

— acute MS (<3 months);

— relapsing acute MS (2-4 episodes of acute sinusitis per year);

— chronic rhinosinusitis (CRS) (>3 months);

- exacerbation of chronic MS (intensification of existing and/or appearance of new symptoms).

A more concise classification is formulated in the EP3OS recommendations (2007):

— acute MS (less than 12 weeks until complete resolution of symptoms);

— CRS (symptoms persisting for more than 12 weeks).

According to the severity of the disease, there are also several classification options based on fundamentally different criteria.Based on the severity of clinical and radiological signs, it is proposed to distinguish the following forms of MS:

- mild: nasal congestion, mucous or mucopurulent discharge from the nose and/or into the nasopharynx, body temperature up to 37.5 ° C, headache, weakness, hyposmia; on the radiograph of the SNP, the thickening of the mucous membrane is no more than 6 mm;

- moderate: nasal congestion, purulent discharge from the nose and/or into the nasopharynx, body temperature above 37.5 ° C, pain and tenderness on palpation in the projection of the affected SNP, headache, hyposmia, pain may radiate to the teeth, ears, general malaise; on the X-ray of the SNP - thickening of the mucous membrane more than 6 mm, a total decrease in pneumatization or fluid level in one or two sinuses;

- severe: nasal congestion, copious purulent discharge from the nose and/or into the oropharynx (but may be absent), body temperature above 38°C, severe pain on palpation in the projection of the SNP, headache, anosmia, severe weakness; on the radiograph there is a total decrease in pneumatization or fluid level in more than two EDs; in the general blood test - leukocytosis, shift of the formula to the left, acceleration of ESR; orbital, intracranial complications or suspicion of them [E. Araujo 2003].

In the EP3OS recommendations (2007), the severity of the disease is determined based on a subjective assessment of the severity of MS symptoms using a visual analogue scale (VAS) (0-10 cm):

— 0—3 — mild severity of the symptom;

- >3-7 - moderate;

- >7-10 - pronounced.This approach to determining the severity of MS may be explained by the fact that in most European countries and America, this disease is initially treated by a general practitioner, who usually does not use anterior rhinoscopy. Moreover, some authors believe that endoscopy of the nasal cavity, CT examination, and bacteriological examination of the contents of the SNP are not necessary for making a diagnosis. In their opinion, these studies are additional and are required only in case of long-term persistent course of the disease, ineffectiveness of the antibacterial treatment, or in case of significant severity of symptoms. Radiography of the ED in acute MS is not generally considered indicated , since a decrease in the pneumatization of the ED is detected even with a banal acute respiratory viral infection in approximately 87% of the examined patients. Thus, definitions, recommended diagnostic methods and treatment methods can vary widely depending on the standards adopted in a particular country [Fokkens W. 2007].

Etiology and pathogenesis of CRS

Depending on the etiological factors, CRS is divided into bacterial, fungal (invasive and non-invasive forms) and caused by bacterial-fungal associations. According to the morphological features, CRS can be catarrhal, purulent, polyposis-purulent and polyposis, and the latter form - PRS - is often described as a separate disease. However, CRS is considered a multifactorial disease, as there are more than a dozen confirmed causes and predisposing factors.

Currently, the most popular rhinogenic theory of the pathogenesis of CRS; inflammatory processes in the ED as a result of trauma, specific, odontogenic sinusitis are much less common [Brook I. 2006]. The modern theoretical basis for functional intranasal surgery, based on the fundamental works of W. Messerklinger and H. Stammberger, suggests that chronic inflammation in the mucous membrane of the urinary tract is a consequence of impaired aeration. In typical cases, the leading role in the pathogenesis of CRS is played by pathological changes in the area of the middle nasal passage, where the ostiomeatal complex (OMC) is located - the location of the outlet openings of the maxillary, frontal sinuses and the anterior cells of the ethmoidal labyrinth [Neubauer N., März R.W. 1994].

Morphological studies have proven that in adjacent areas of the mucous membrane, the ciliary movement of the cilia of epithelial cells becomes ineffective, and mucociliary transport stops [].Thus, even a slight swelling of the mucous membrane is enough to disrupt normal aeration, which leads to a slowdown in mucociliary transport, a decrease in the partial pressure of oxygen in the sinuses, and a disruption in the evacuation of secretions from the SNP [Stammberger H 1991]. This, in turn, promotes adhesion and longer contact of pathological agents and further damage to the mucous membrane, the manifestation of inflammation. Some authors [März R.W., Ismail C 1999] suggest that typical causes of impaired drainage and aeration of the SNP are anomalies in the structure of the OMK, such as:

- bullous, paradoxically curved, doubled or enlarged due to the bone frame or soft tissues of the middle turbinate;
- deployed, curved, pneumatized uncinate process, in contact with the lateral surface of the middle turbinate;
- hyperpneumatization of the ethmoidal bulla, suprabular cell (agger nasi), infraorbital cell (Haller cell);
- spines and ridges of the nasal septum, especially those located at the level of the middle concha;
— additional anastomosis of the upper quadrant.

Mucociliary transport on the inner and outer surfaces of the medial wall of the upper jaw occurs in opposite directions. This, in the presence of an additional anastomosis, creates a condition for the recirculation of mucus from the nasal cavity back into the sinus, and also creates the preconditions for the formation of cysts and antrochoanal polyps [Fokkens WJ. 2012]. Postoperative additional anastomosis in the lower nasal meatus can also contribute to and maintain the inflammatory process in the maxillary sinus. However, some authors state that there is no statistically confirmed correlation between the presence of changes in the area of the circulatory system and the occurrence of CRS [März R.W., Ismail C 1999]. There is also no clear opinion regarding the influence of a curvature of the nasal septum on the morphogenesis of CRS, since there is no clear definition of the “curvature” itself. It is believed that this term means a deviation of the structures of the nasal septum from the midline by 3 mm or more. Some authors [Brook I. 2006] show in evidence-based studies that a deviated nasal septum is a predisposing factor for the development of CRS, while others [Stammberger H 1991] claim the opposite. Thus, the role of anatomical variants in the structure and pneumatization of the structures of the ethmoidal labyrinth and CMC in the pathogenesis of CRS cannot be considered unambiguously proven. It is believed that in CRS, not only the mucous membrane is involved in inflammation, but through the Haversian canals the process reaches the periosteum, resulting in the development of local osteitis [Fokkens WJ. 2012]. These changes on CT are represented by thickening and increased density of the periosteum and cortical bone of the maxillary, sphenoid, less commonly the frontal sinus and paper plate, while the intersinus septa in the ethmoidal labyrinth may be thinned.

The aim of the study: To optimize the diagnosis, treatment and prevention of chronic rhinosinusitis in school-age children.

Materials and methods

A comprehensive study of the effectiveness of using low-frequency ultrasound for the treatment of chronic rhinosinusitis in children was carried out on the basis of the children's department of the multidisciplinary regional hospital in the city of Bukhara between 2022 and 2023. The study included 78 patients with an average age of 10.3 years, diagnosed with chronic bacterial rhinosinusitis. Low-frequency ultrasonic cleansing of the nasal cavity was performed with using an ultrasonic device Fotek AK 101 with a resonant frequency 25 kHz. As

a solution for cavitation by low frequency ultrasound a 0.9% sodium chloride solution was used. It promotes separation pus, mucus, fibrin films. This technique is used in an outpatient ENT office for children.

Result and discussion

All patients were comprehensively examined: standard examination of ENT organs, general clinical laboratory tests studies, computed tomography or x-ray examination of the paranasal sinuses, cytology of discharge from the nasal mucosa, microbiology of discharge from the middle meatus of the nasal cavity, assessment of the functional state of nasal breathing and were divided into two groups by random sampling.

Group I (main) consisted of 53 patients who received sanitation of the nasal cavity with low-frequency ultrasound; Group II – 25 patient without sanitation low frequency ultrasound. The groups of patients were comparable in age, gender, somatic diseases and diseases of the ear, throat, nose All patients received complex therapy for chronic rhinosinusitis: vasoconstrictor drugs, mucolytics, topical drugs (antimicrobial, anti-inflammatory). Patients in the main group received additional irrigation nasal mucosa using low-frequency ultrasound and sterile sodium chloride solution 0.9%. The procedure was performed from the first day of the patient's treatment after a comprehensive diagnosis, once every day, once a day, the average number of procedures was 3.4

On the first computed tomogram, all patients noted the presence of purulent exudate in the maxillary sinuses. Before treatment, patients in two groups experienced nasal congestion, purulent nasal discharge, and various headaches. After the first day from the start of treatment, no statistically significant differences in changes in the clinical manifestations of rhinosinusitis were observed between the groups. However, on the third day of treatment, 42 (77.8%) of 53 patients receiving low-frequency ultrasound against 23 (56.1%) of 25 patients from group II, nasal breathing was practically restored, with periodic, partial nasal obstruction noted ($p < 0.05$); in 38 (70.4%) group I (main), versus 18 (43.9%) of group II patients, there is a predominance of mucous secretion in scanty amount, absence of purulent discharge ($p < 0.05$); head pain was absent in patients of the main group in 52 (98.2%) patients, in difference from the control group – in 23 (92.7%) patients ($p < 0.05$); The body temperature of patients ranging from 36.3 to 36.7 □C is observed equally in the two groups ($p > 0.05$). When comparing groups I and II, statistically significant differences in favor of the main group I were noted in terms of nasal obstruction and purulent discharge. Despite complex therapy, complications in the form of unilateral otitis media was observed in group I in 2 (3.7%) patients, in group II – in 6 (14.6%) patients. Thus, the complicated course of chronic rhinosinusitis in patients of the main group is statistically significantly less common ($p < 0.05$) than in patients of the control group. Irrigation of the nasal mucosa and middle meatus sterile sodium chloride solution 0.9%, cavitated by low-frequency ultrasound, highly effective for the treatment of chronic rhinosinusitis in children.

Findings

1. The advantage of the ultrasonic method over simple treatment of the source of inflammation is the additional mechanical effect on the tissue, which helps break down bacterial films created from pathogenic and opportunistic microorganisms that prevent the flow of drugs to biological tissues.

2. The proposed technique is highly effective and promising, since its use cleanses the nasal cavity and paranasal sinuses, and at the same time it is non-invasive, painless, easy to implement and economically low-cost.

LIST OF REFERENCES:

1. Yanov Yu.K. etc. Practical recommendations for antibacterial therapy for sinusitis (a manual for doctors). /St. Petersburg, 2019; P. 23.
2. Garashchenko T.I., Ilyenko L.I., Garashchenko M.V. Elimination therapy in seasonal influenza prevention programs and ARVI //Russian Medical Journal. 2020;13(1):52-5.
3. Operating manual for AUZH-100-Fotek. /Ekaterinburg, 2019; P. 5.
4. Krivoshein Yu.S., Rudko A.P., Svistov V.V. Miramistin is an antiseptic with immunomodulating and regeneration-enhancing properties //Abstracts of reports of the VII Russian National Congress "Man and Medicine". M., 2018; P. 509.
5. Yanov Yu.K. etc. Practical recommendations for antibacterialtherapy for sinusitis (a manual for doctors). / St. Petersburg, 2021; P. 23.
6. Garashchenko T.I., Ilyenko L.I., Garashchenko M.V. Elimination therapy in seasonal influenza prevention programs and ARVI //Russian Medical Journal. 2016;13(1):52-5.
7. Operating manual for AUZH-100-Fotek. / Ekaterinburg, 2009; P. 5.
8. Krivoshein Yu.S., Rudko A.P., Svistov V.V. Miramistin is an antiseptic with immunomodulating and regeneration-enhancing properties //Abstracts of reports of the VII Russian National Congress "Man and Medicine". M., 2018; P. 509.

Entered 20.04.2024