New Day in Medicine
Новый День в Медицине
NDM

TIBBIYOTDA YANGI KUN

Ilmiy referativ, marifiy-ma'naviy jurnal

AVICENNA-MED.UZ

ISSN 2181-712X.
EiSSN 2181-2187
1 (75) 2025

ТИББИЁТДА ЯНГИ КУН
НОВЫЙ ДЕНЬ В МЕДИЦИНЕ
NEW DAY IN MEDICINE

Илмий-рефератив, маънавий-маърифий журнал
Научно-реферативный,
духовно-просветительский журнал

УЧРЕДИТЕЛИ:

БУХАРСКИЙ ГОСУДАРСТВЕННЫЙ МЕДИЦИНСКИЙ ИНСТИТУТ
ООО «ТИББИЁТДА ЯНГИ КУН»

Национальный медицинский исследовательский центр хирургии имени А.В. Вишневского является генеральным научно-практическим консультантом редакции

Журнал был включен в список журнальных изданий, рецензируемых Высшей Аттестационной Комиссией Республики Узбекистан (Протокол № 201/03 от 30.12.2013 г.)

1 (75)

2025

январь

www.bsmi.uz
https://newdaymedicine.com E: ndmuz@mail.ru
Тел: +99890 8061882

Received 20.12.2024, Accepted: 03.01.2025, Published: 10.01.2025

UDK 618.19:616–006.06:616–07

KO‘CRAK SUT BEZY SARATONIDA RANDIOLOGIK VA MORFOLOGIK XUSUSIYATLARNING QIYOSIY TA’RIFI

Axmadova Maftuna Amin qizi Email: AxmadovaM@mail.ru

Abu Ali ibn Sino nomidagi Buxoro davlat tibbiyot instituti, O‘zbekiston, Buxoro sh.
A. Navoiy kochasi 1 Tel: +998 (65) 223-00-50 e-mail: info@bsmi.uz

✓ ***Resume***

Mammografiya oddiy, sub'ektlar uchun nisbatan xavfsiz va yuqori diagnostik samarali tasvirlash usuli bilan ajralib turadi, bunda sut bezi o'smalarini aniqlash 80% ga yetadi. U sut bezidagi o'zgarishlarni hujjatlashtirish va uning holatini dinamik kuzatish imkonini beradi va bir qator afzalliklarga ega. Ko'pgina mamlakatlarda mammografiya sut bezi kasalliklarini tashxislashda qo'llaniladigan birinchi usuldir. Yuqori mammografik zichlik, ayniqsa, erta bosqichlarda sut bezi saratoni tashxisini qiyinlashtiradi. Sut bezi kasalliklarini tashxislashning muhim usuli ultratovush tekshiruvi hisoblanadi. Sut bezi kasalliklarda ultratovush tekshiruvining afzalliklari nurlanishning yo'qligi va bir nechta tekshiruvlar imkoniyatini o'z ichiga oladi. Maqolada sut bezi saratoni prognozida RE, RP, Her2/neu, KI67 markerlarning ta’sirining ahamiyati, o’simta tomirlarining mavjudligi va zichligi o’rtasida to’g’ridan-to’g’ri proportsional bog’liqlik mavjudligi, bemorlarda proksimal omillarning bashoratlash tartibi asoslangan.

Kalit so’zlar: sut bezi saratoni, mammogarfiya, fibroademona, kalsifikatsiya

COMPARATIVE DESCRIPTION OF RADIOLOGICAL AND MORPHOLOGICAL CHARACTERISTICS IN BREAST CANCER

Axmadova Maftuna Amin qizi Email: AxmadovaM@mail.ru

Bukhara State Medical Institute named after Abu Ali ibn Sina, Uzbekistan, Bukhara,
st. A. Navoi. 1 Tel: +998 (65) 223-00-50 e-mail: info@bsmi.uz

✓ ***Resume***

Mammography is simple, relatively safe for subjects, and is characterized by a high diagnostic efficiency imaging method, in which detection of breast tumors reaches 80%. It allows you to document the changes in the mammary gland and dynamically monitor its condition and has a number of advantages. In many countries, mammography is the first method used to diagnose breast diseases. High mammographic density makes it difficult to diagnose breast cancer, especially in the early stages. Ultrasound examination is an important method for diagnosing mammary gland diseases. The advantages of ultrasound in breast diseases include the absence of radiation and the possibility of multiple examinations. In the article, the importance of RE, RP, Her2/neu, KI67 markers in the prognosis of breast cancer, the existence of a direct proportional relationship between the presence and density of tumor vessels, and the predictive procedure of proximal factors in patients are based.

Key words: breast cancer, mammography, fibroademona, calcification

СРАВНИТЕЛЬНАЯ ОПИСАНИЕ РАДИОЛОГИЧЕСКИХ И МОРФОЛОГИЧЕСКИХ ХАРАКТЕРИСТИК ПРИ РАКА МОЛОЧНОЙ ЖЕЛЕЗЫ

Ахмадова Мафтуна Аминовна Email: AxmadovaM@mail.ru

Бухарский государственный медицинский институт имени Абу Али ибн Сины,
Узбекистан, г. Бухара, ул. А. Навои. 1 Тел: +998 (65) 223-00-50 e-mail: info@bsmi.uz

✓ ***Резюме***

Маммография проста, относительно безопасна для обследуемых, отличается высокой диагностической эффективностью метода визуализации, при котором выявляемость опухолей молочной железы достигает 80%. Он позволяет документировать изменения молочной железы и динамически контролировать ее состояние и имеет ряд преимуществ. Во многих странах маммография является первым методом диагностики заболеваний молочной железы. Высокая маммографическая плотность затрудняет диагностику рака молочной железы, особенно на ранних стадиях. Ультразвуковое исследование является важным методом диагностики заболеваний молочной железы. К преимуществам УЗИ при заболеваниях молочной железы относятся отсутствие радиации и возможность многократного обследования. В статье рассмотрено значение маркеров RE, RP, Her2/neu, KI67 в прогнозе рака молочной железы, наличие прямой пропорциональной зависимости между наличием и плотностью сосудов опухоли, методика прогнозирования проксимальных факторов у больных у основанный.

Ключевые слова: рак молочной железы, маммография, фиброадемона, кальцификация.

Indraduction

With the increasing number of oncological diseases worldwide, the diagnosis and treatment of the disease is becoming one of the urgent problems. The official data of the world medical statistics shows that there is an increase in oncological diseases worldwide. According to the statistics of the World Health Organization (WHO), "by 2030, the number of patients with poor-quality tumor disease will be 15 million worldwide, but the early diagnosis and treatment of oncological diseases, and the prediction system after systemic treatment of oncological diseases are still unclear." . Much research has been done on the course and diagnosis of breast cancer in women, but there are few, and in this regard, our research is expected to help fill the gap in the evaluation and scientific research of this oncological pathology. It consists of a unique scientific study dedicated to early and correct diagnosis and prognosis of breast cancer. Therefore, radiological and pathomorphological and molecular-genetic characteristics of breast cancer are one of the most important problems of basic medicine and oncology. Breast cancer incidence in Uzbekistan is 11.2 per 100,000 population. The prognosis of this disease depends on the stage of the process, so it is very important to detect breast tumor in the early stages. It is also important to determine the nature of the tumor, because it is related to the next stage of treatment of the patient. Identifying mammary tumors, their comparative diagnosis, evaluation of the spread and stage of the tumor process is one of the most important problems of modern oncology, therefore, developing the diagnosis and prognosis of mammary tumors is an urgent task [2,11,14].

There are three types of tumor malignancy - low, medium and high, pathogistologically determined on the basis of tissue and cellular atypia, tubular and channel-like structures, mitotic division and hyperchromatosis of cells, and the results is taken. Its detection is related to the treatment and prognosis of the disease. Standard examinations of patients with suspected breast cancer include mammological examination, ultrasound examination and X-ray mammography. Many studies have confirmed that the diagnosis of breast cancer in the early stages can have a decisive effect on timely medical care and reduce the death rate from this disease.

Butun dunyoda sut bezi saratoni tashxisida rentgenmammografiya va sonografiya tekshiruvlarining ahamiyatini o‘rganishga qaratilgan ilmiy tadqiqotlar hali ham olib borilmoqda. Shu nuqtai nazardan, rentgenmammografiyasi (RM) va ultratovush bo'yicha sut bezi saratonining o’ziga xos xususiyatlarini aniqlash va ularning sut bezi saratonini qiyosiy tashxislash samaradorligini solishtirish muhimdir. Sut bezi saratonining immunogistologik turlarining rentgenmammografiyaning ko'rsatkichlariga ta'sirini asoslash, shuningdek, tekshirish algoritmidagi roli va o'rnini baholash alohida ahamiyatga ega [13,14,16].

Purpose of the study: to study the radiological and morphological characteristics of breast cancer, to study the markers RE, RP, Her2/neu, KI67 in the prognosis of breast cancer with the correlation of the presence of a direct proportional relationship between the presence and density of tumor vessels.

Material and methods

For the purpose of scientific justification of the research works, patients with a total of 100 volume derivatives, who were examined in 2023-2024 at the department of mammology and pathological

anatomy of the RIO and RIATM branch of Bukhara region, were selected for the purpose of diagnosis. In each of them, the tissue taken from the tumor and the prepared histological materials were studied and examined using morphological and immunohistochemical methods. Patients with low-grade tumors (80) and good-grade tumors (20) were divided into two groups, and the control group.

1 – table Distribution of patients by age

Age (years)	Dangerous tumors (n=80)		Benign tumors (n=20)	
	абs.	%	абs.	%
29 age	4	5.0	3	15.0
30-39	9	11,3	10	50.0
40-49	31	38,8	6	30
50-59	21	26,3	1	5.0
60-69	12	15.0	-	-
70 old age	3	3,7	-	-
Total	80	100,0	20	100,0

The age of the patients ranged from 29 to 82 years, and the average age was 43.9±2.2 years. It is worth saying that the disease was observed in the age range of 40-50 in most cases - 79.9%.

All patients underwent X-ray mammography in two projections. From all patients diagnosed as dangerous and safe, histologically confirmed samples were taken and the nature of the tumor was determined. Then the material was mounted on a glass slide. After installation, the material was sent to the morphological department, which allows it to be prepared for work. After the slides are processed and examined, all specimens are embedded in paraffin to obtain histological blocks that allow differentiation of tumor nosology. The next stage of immunohistochemical research is microtomy - a laboratory assistant makes sections from paraffin blocks with a thickness of up to 1.0 microns and places them in special microscopes. Then immunohistochemical examination is carried out in order to distinguish the phenotype of mammary tumor.

Statistical processing of the research results was carried out using the "Statistica for Windows 7.0" personal computer application package. The study presents a table on the distribution of biopsy materials of a total of 100 selected patients with asthma according to histological examinations.

2- table

O‘smaning morfologik turi	Number of patients n=100	%
Fibroadenoma	14	14.0
Lipoma	4	4.0
Atheroma	2	2.0
Invasive ductal cancer	69	69.0
invasive lobular cancer	7	7.0
Medullary cancer	2	2.0
Mucinous cancer	2	2.0
Total	100	100

From table 2, it can be seen that invasive ductal cancer 69 (69%) is the most common of safe types of tumors (Figures 1 and 2), while medullary and mucinous types are the least common malignant tumors. from 2% and 2%, respectively (Figures 3 and 4).

Among safe tumors, fibroadenoma was the most frequent with 14%, while atheroma was the least safe tumor (2%).

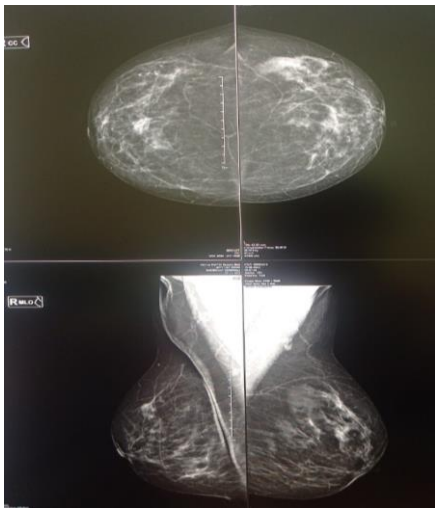
A 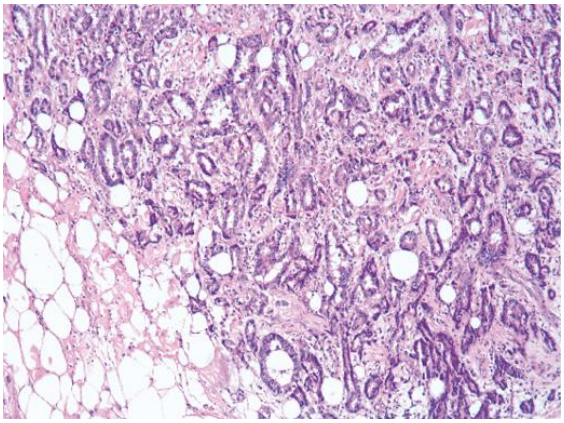
B

Figure 1. Patient R, 45 years old. A – X-ray mammography is imaged in two projections. In the center of the right mammary gland, an uneven inhomogeneous shadow with a contour of 91x85.5 mm was detected. BI-RADS R - 4b.

B-Invasive ductal breast cancer grade G1 was determined. Cancer structures repeat the structure of mammary gland ducts, but there are separate complexes of tumor cells in the stroma, which confirms the invasive type of growth. Infiltration of adipose tissue was noted. Hematoxylin-eosin, x100, IGX – Luminal A type (ER - +++ PR - +++ , HER2 - negative , Ki67-10%)

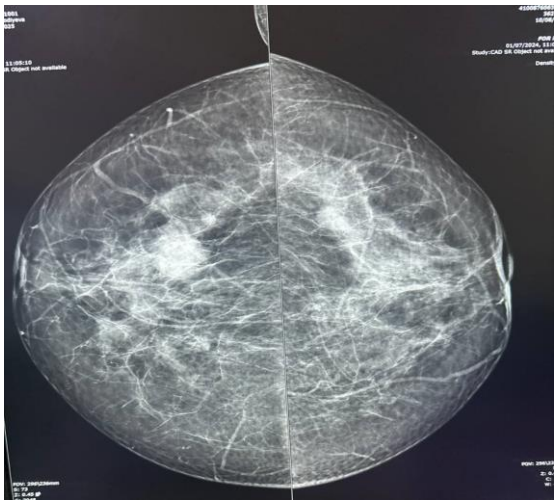

A
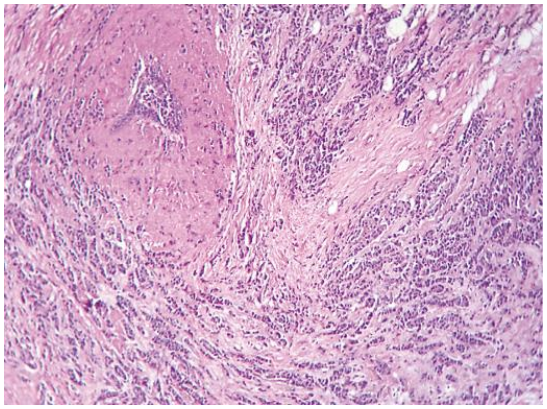
B

Picture 2. Patient T., 45 years old. A- X-ray mammography revealed an uneven inhomogeneous shadow with a contour of 42x38 mm in the upper outer quadrant of the right mammary gland in two projections. BI-RADS R4a. Invasive lobular breast cancer G-2 cells were detected.

Cancer cells are small and form separate chains. There are hyaline foci in the stroma. Hematoxylin-eosin, x200. Luminal V Her2/neu negative (ER - + PR - + , HER2 negative, Ki67-30%)


A
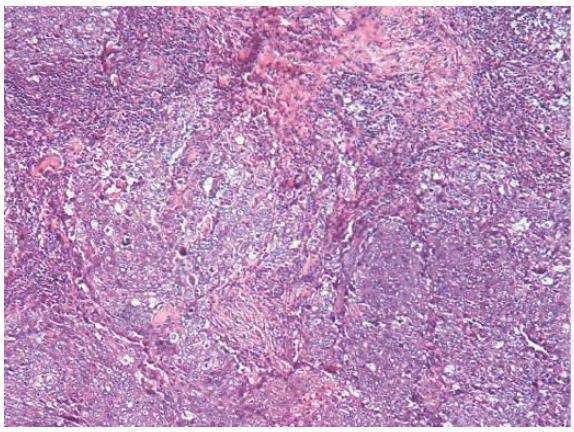
B

Picture 3. Patient U., 47 years old. X-ray mammography was obtained in two projections. A 26.5x18mm inhomogeneous shadow was detected in the lower inner quadrant of the left mammary gland. Medullary breast cancer. Layers of tumor cells against the background of lymphocytic infiltration of the stroma. Hematoxylin-eosin, x100, in immunohistochemical examination - a negative type was found three times (ER - negative PR - negative, HER2 negative, Ki67-10%)

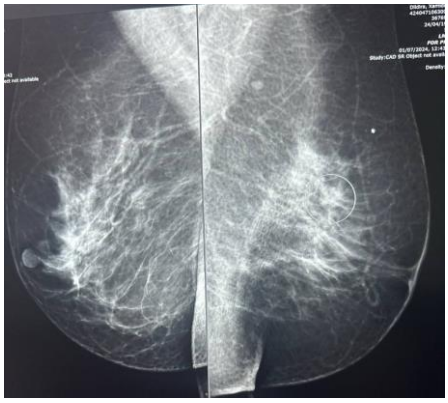
A
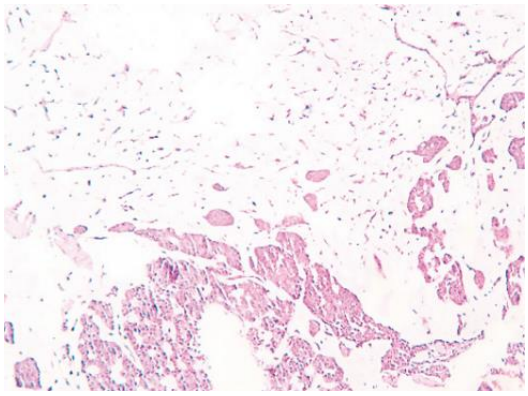
B

Picture 4. Patient Z., 42 years old. X-ray mammography was obtained in two projections. A 13.5x12mm shadow was detected in the upper outer quadrant of the left mammary gland. BI-RADS 4b. Mucinous breast cancer. Mucin is a collection of tumor cells between tissues. Hematoxylin-eosin, x100, IGX - Hyperexpression Her2/neu type (ER - + PR - + , HER2 +++, Ki67-20%)

Tumors were characterized by the degree of cell differentiation. This is shown in the table below.

3 - jadval

Histological structure and aggressiveness of tumors - grade G

Cell differential level	Number of patients, n=80	%
G_1	12	15,0
G_2	43	53,7
G_3	25	31,25

As can be seen from table 3, in 68 (85%) cases, the aggressiveness of a low-quality tumor was determined - G2, G3 form, in 12 (15%) cases, low aggressiveness - G1.

In each of them, the histological materials from which the tumor was removed and prepared were studied, the presence of dangerous and safe types of tumors in each of them and the isolated cases were examined by histochemical methods.

Table 4 Distribution of IGX in patients by status

IGX status	Bemorlar soni, (n=80)	
	n	%
Luminal A	27	33,75
Luminal V Her2/neu negative	9	11,25
Her2/neu positive	13	16,25
Hyperexpression of Her2/neu	11	13,75
Triple negative	17	21,25
Total	80	100

The results of IGX are presented in the table below.

Shows that the most common type of IGX is luminal type A. Luminal Her2/neu negative type 9 (11.25%) was the least frequent.

LIST OF REFERENCES:

1. Семиглазов В.Ф., Нургазиев К.Ш. Семиглазов В.В. Руководства: Общие рекомендации St. Gallen-2015 по лечению раннего рака молочной железы //Адаптированные экспертами российского общества онкомаммологов [РООМ] Издательство Алматы. 2015. 71 с.
2. Семиглазов В.Ф., Нургазиев К.Ш. Семиглазов В.В. Руководства: Общие рекомендации St. Gallen-2015 по лечению раннего рака молочной железы //Аадаптированные экспертами российского общества онкомаммологов [РООМ] Издательство Алматы. 2015. -71 с.
3. Сенча А.Н. Ультразвуковое исследование молочных желез /М.: Москва. ´МЕДпресс информ. 2018; 115 с.
4. Синюкова Г.Т. Использование энергетической допплерографии опухолей молочной железы в прогнозировании поражения регионарных лимфоузлов /Тезисы II съезда онкологов закавказских государств (Баку 19-21 мая. 2001) 2021; 158 с.
5. Серебрякова С.В. Магнитно-резонансная семиотика рака молочных желез //Опухоли женской репродуктивной системы. 2009;3:20-25.
6. Сергеев П.В., Панов В.О., Волобуев А.И. Новые технологии в диагностике опухолевых образований молочной железы с использованием магнитно резонансных контрастных средств //Медицинская визуализация. 2005;3:104.
7. Труфанов Г.Е. Руководство по лучевой диагностике заболеваний молочных желез //СПб.: -ЭЛБИ-СПб. 2009; 351 с.
8. Филатов А.В. Архив патологии. 2009;1:53-56.
9. Фомин Ю.А. Рентгеноанатомический атлас молочных желез // СПб.: Гиппократ. 2003;168.
10. Хайленко В.А., Комова Д.В. Диагностика рака молочной железы // Под редакцией В.А. Хайленко. - М.: ООО «МИА». 2005; 240с.
11. Хасанов Р.Ш. Мастопатия: Руководство для врачей / Казань. 2006; 216 с.
12. Харченко В.П. Рожкова Н.И. Клиническая маммология // 1-е изд. - М. 2005; 200с.
13. Хохлова Е.А. Возможности ультразвуковой эластографии в комплексной диагностике заболеваний молочной железы /Дисс. …к.м.н. 14.01.13. -М.: 2010; 147с.
14. Чёрная А.В. Сравнительный анализ информативности цифровой маммографии и маммосцинтиграфии в диагностике рака молочной железы /Автореферат дисс. …к.м.н. 14.01.12. -М.: 2018; 25с.
15. Чувашев И.Р. МРТ диагностика заболеваний и опухолей молочных желез /Дис. … к.м.н. 14.01.19. - Казань. – 2009; 136с.
16. Abdel-Hadi M, Abdel-Hamid GF, Abdel-Razek N. Should fine-needle aspiration cytology be the first choice diagnostic modality for assessment of all nonpalpable breast lesions? The experience of a breast cancer screening center in Alexandria, Egypt //Diagnostic Cytopathology. 2010;38(12):880-889.

Entered 2012.2024